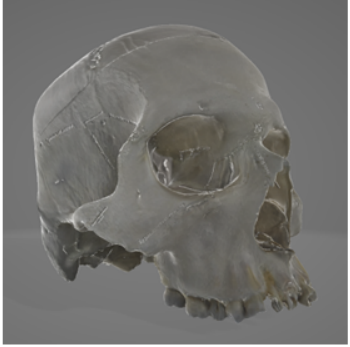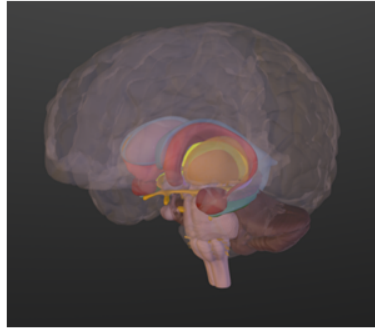


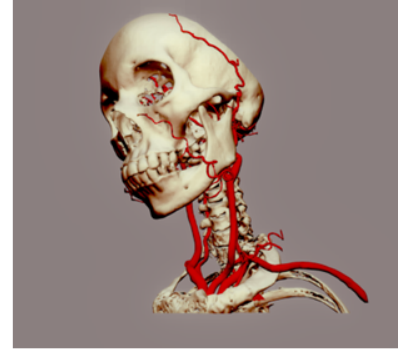
Skull sutures



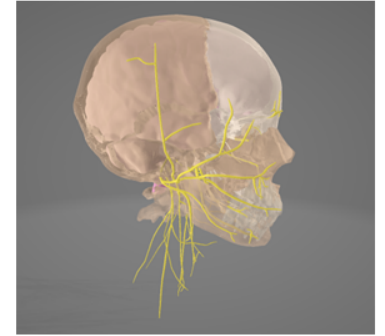
Limbic System




Arteries of head and neck



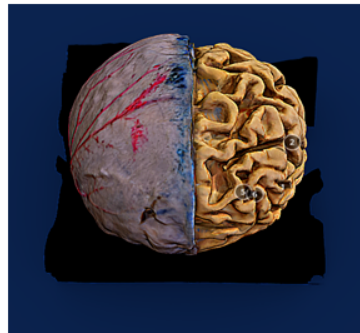
Cranial Nerves



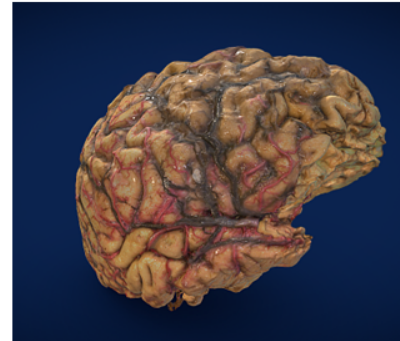
Brain surface



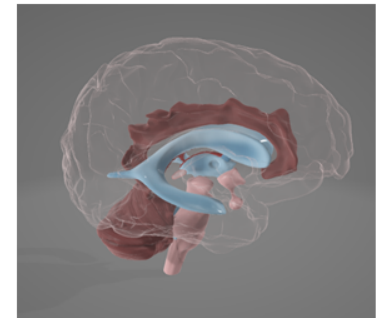
Alzheimer's brain




Brain Hemisected



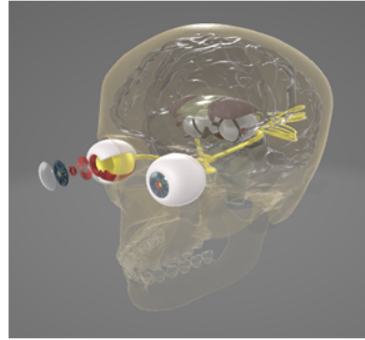
Brain Ventricles



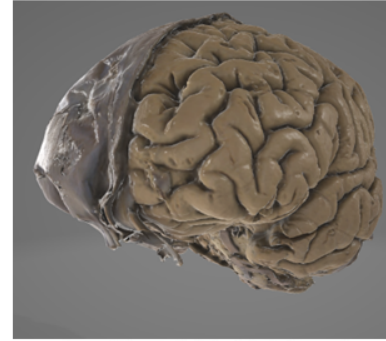
## Neuronal Cell Environment



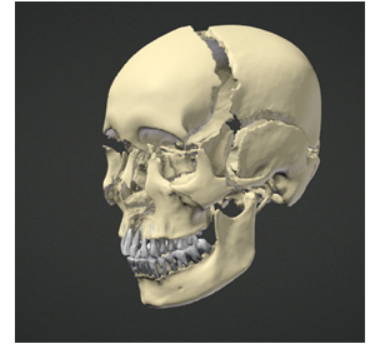
## Visual Pathway



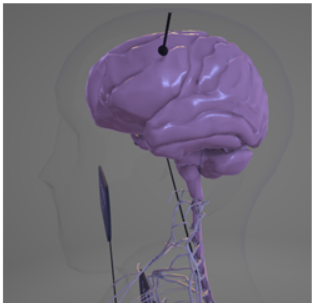
## Brain Coverings



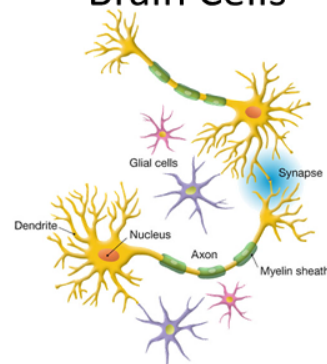
## Duchenne Skull



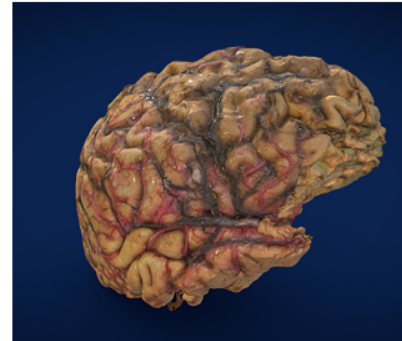
## Nervous System



## Brain Cells



## Brain Hemisected



## Brain Regions

